CARDIAC TESTS & IMAGING

Cardiac MRI
What will my heart scan tell me?

The short answer

Cardiac MRI (CMR) uses a strong magnet and radio waves to make detailed pictures of your heart, without X-rays. It can assess **how well the heart pumps, the condition of its muscle** and, when stress perfusion is included, whether its blood supply is adequate. [1,3]

Different images answer different questions

One appointment combines several short scans, called **sequences**, into a **protocol**. These are chosen to investigate a particular problem, such as a weak or thickened heart, suspected inflammation, previous damage or possible angina. **Not every MRI includes a stress test.** [3,6]

Cine imaging

How does the heart move?

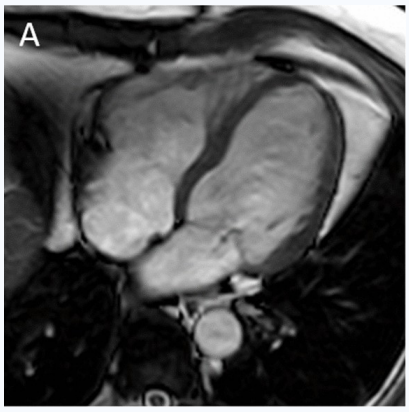

One frame from a moving film of the heartbeat.

Cine images show how the chambers fill and squeeze, and whether each part of the muscle moves normally. We measure chamber volumes, muscle thickness and **ejection fraction**: the proportion of a chamber's blood pumped out with each beat. This helps assess a weak, enlarged or unusually thick heart and provides a baseline for follow-up. [3,6]

Tissue mapping

What is happening in the muscle?

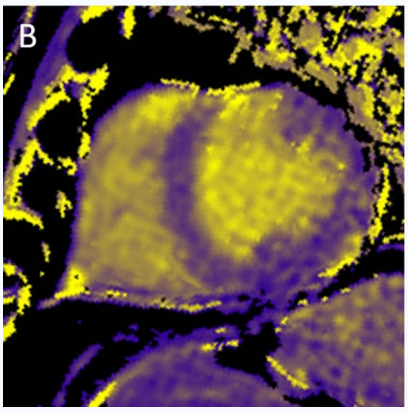

A native T1 map. Colours represent measured tissue values.

T1 and T2 maps turn measurements of the muscle's MRI signal into maps. They can reveal changes associated with swelling, inflammation or more widespread tissue disease, including changes that are difficult to see on ordinary images. The numbers are compared with reference ranges for that scanner and technique. **Colour alone does not establish a diagnosis.** [13]

LGE imaging

Is there a pattern of injury or scar?

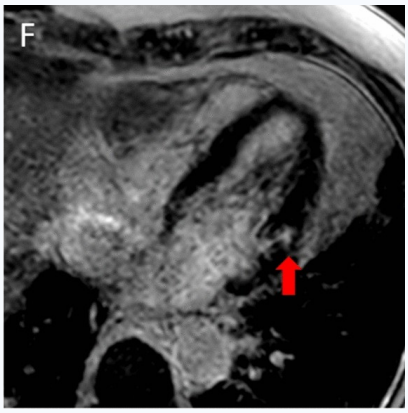

The original red arrow marks focal fibrosis (scar).

Late gadolinium enhancement (LGE) images are taken after a contrast injection. Some areas of injury or scar handle the contrast differently and appear brighter. Their pattern helps distinguish previous heart-attack damage from other causes of injury, such as **myocarditis** (heart-muscle inflammation) or **cardiomyopathy** (heart-muscle disease). LGE is interpreted alongside mapping and pumping function. [3,6]

Real images from one published examination. Adapted from Giollo et al. (2021), Fig. 2A, B and F, CC BY 4.0. Panels cropped and rearranged; image content and original arrow unchanged.

Other protocols: stress perfusion assesses blood supply (page 3). Targeted sequences can measure valve leakage, examine the aorta and congenital heart conditions, or investigate iron overload. [3,6]

CARDIAC TESTS & IMAGING

MRI, CTCA and echo: how do they fit together?

These tests look at the heart in different ways. The choice depends on your symptoms, the question being asked and what previous tests have already shown.

Investigation	What it is particularly useful for
Echocardiography Ultrasound	Often the first assessment of breathlessness, a murmur or suspected pumping problems. It shows moving chambers and valves, and measures blood flow. Stress echo can also look for a blood-supply problem (**ischaemia**). [5,6]
CT coronary angiography CTCA: X-rays + iodine-based contrast	Provides detailed pictures of the main coronary arteries: **plaque in their walls and narrowing of the blood channel**. It is often used to investigate suspected stable angina. [2,4]
Cardiac MRI Magnet + radio waves	Measures chamber size and pumping, and examines **muscle tissue for patterns of inflammation, injury or scar**. Stress perfusion can assess blood supply when included. MRI can clarify uncertain echo measurements or investigate a muscle abnormality. [1,6]

Why is routine MRI not a plaque test?

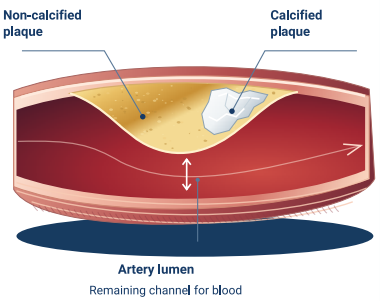

Plaque is in the artery wall. The remaining channel carries blood. Illustration, not a scan.

Plaque sits **in the wall of a coronary artery**. Assessing it requires fine detail in small, thin structures that move with the heartbeat and breathing. CTCA is designed to show the artery wall and blood channel. Routine MRI does not reliably map or exclude coronary plaque. [1,2,9]

MRI can show an **effect on the muscle**: a blood-supply problem during stress or a scar from previous damage. Plaque can still be present when pumping and stress perfusion are reassuring.

Specialist coronary MRI can show artery origins and course; coronary plaque MRI remains a research technique. [6,9]

When MRI adds to another test

After an echocardiogram

"The heart is pumping less strongly. Why?"
MRI can measure reduced pumping in detail and look for patterns of previous damage, inflammation or another muscle condition. This can guide treatment and follow-up. [6]

After CTCA

"There is a narrowing. Is it limiting blood supply?"
CTCA shows the artery and narrowing. Stress MRI assesses the supplied muscle when the effect of the narrowing on blood flow remains uncertain. [4,5]

Each test should answer a useful question

You do not automatically need all three tests. A normal MRI is reassuring about the questions it examined; it does not mean the coronary arteries are free of plaque.

CARDIAC TESTS & IMAGING

Stress perfusion MRI: investigating angina

Perfusion means blood delivery to the heart muscle. **Angina** is chest discomfort when the heart does not receive enough blood for its needs, often during activity. Stress perfusion MRI asks whether blood supply can increase appropriately. [4,5,10]

How does the stress part work?

You remain lying in the scanner. A medicine, commonly **adenosine**, temporarily widens the small coronary blood vessels and increases blood flow. An area supplied through a significant narrowing may have less capacity to increase its supply, producing a relative shortfall during stress. This tests blood-flow reserve; it does not simply make the heart beat faster. [3,10]

A **gadolinium contrast agent** is injected into a vein while rapid MRI pictures track its passage through the muscle. The doctor checks areas with different contrast arrival against cine and LGE images. This helps distinguish a blood-supply problem from previous damage or an imaging artefact. Some protocols also measure blood flow numerically. [3,10]

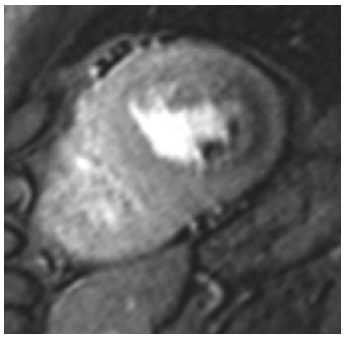

What a perfusion image can show

This real first-pass image shows a darker region in the lateral heart-muscle wall. The source identifies this as a **perfusion defect**: contrast has reached that region differently.

The doctor assesses the full moving sequence and other images. One still frame cannot establish whether an abnormality is caused by a flow-limiting narrowing.

Adapted from Kramer et al. (2020), Fig. 5, CC BY 4.0. Middle panel cropped; image content unchanged.

What might I feel?

Brief flushing, breathlessness, chest pressure or headache can occur. Staff monitor you and can speak to you throughout. Tell them about symptoms immediately; effects usually settle quickly when adenosine is stopped. Other stress medicines may work differently. [8]

What can the result change?

Reassuring perfusion	No significant stress-related blood-supply abnormality was identified in an adequate study. A major flow-limiting narrowing is less likely to explain the symptoms. [4,5,10]
Reduced blood supply Ischaemia	The amount of muscle affected, symptoms and other results guide medicines, further coronary assessment or a discussion about a procedure. **An abnormal scan does not automatically mean a stent.** [5]
An unclear study	Movement, image artefacts or an inadequate stress response can limit the answer. An uncertain result is not the same as a normal result.

A normal stress study has a specific meaning

It does not exclude plaque or every cause of chest pain. Coronary spasm and some small-vessel problems may need further assessment. Continuing or changing symptoms deserve review. [5,10]

CARDIAC TESTS & IMAGING

Preparing for your scan and what to expect

Your scan unit's instructions take priority

Preparation depends on your protocol. Follow your appointment letter about **caffeine, food and medicines**. Caffeine can interfere with vasodilator stress: check which drinks, foods and medicines to avoid, and for how long. Do not stop prescriptions on your own. [7,8]

Tell the team before your visit

Implants, devices or metal

Report a pacemaker, defibrillator, other implant, past operations or possible metal fragments. Some devices can be scanned with specific checks and arrangements; an implant does not automatically rule out MRI. [1,7]

Kidneys, pregnancy and allergies

Report kidney problems, possible pregnancy and previous contrast reactions. A kidney blood test may be requested. MRI uses gadolinium contrast, which is different from iodine-based CT contrast. Cine and some mapping can be done without contrast; LGE and standard stress perfusion usually need it. [1,3,7]

Comfort and communication

Discuss claustrophobia, difficulty lying flat or holding your breath, and any hearing, communication or mobility needs. Ask in advance about support or sedation if needed. [7]

Extra checks for stress MRI

Report asthma or wheeze and relevant rhythm or conduction problems. Bring an up-to-date medicine list and any inhalers you use. The team checks whether the stress medicine is suitable. [8]

From arrival to going home



Illustration of the setup before the table moves in. Your chest is positioned in the centre for imaging; equipment varies.

1. **Prepare**
   Safety checks and ECG stickers, which help time the pictures to your heartbeat. A cannula is placed when contrast or stress medicine is needed.
2. **Take the pictures**
   A receiver coil rests over your chest. Keeping still and following short breath holds reduces blurring. Hearing protection reduces the loud tapping.
3. **Stay in contact**
   Staff can see and hear you. You have an alarm to call for help; report discomfort immediately.

Timing and afterwards: the scan often takes around an hour, but the protocol and appointment length vary. Follow the time in your letter and the unit's discharge advice. Ask about transport and driving if sedation is planned. [7,8]

Benefits and possible downsides

MRI avoids X-rays but needs careful safety screening. Contrast reactions can occur, and gadolinium needs particular consideration in significant kidney disease. Stress medicines can occasionally cause wheeze, low blood pressure or a slow heart rhythm, so suitability checks and monitoring are important. [1,3,8]

CARDIAC TESTS & IMAGING

Understanding your result and the next steps

MRI findings matter because they can change a decision. Your cardiologist considers the whole examination alongside your symptoms, blood tests, ECG and other imaging.

A finding on MRI	What it could change
Reduced pumping function	Can guide heart-failure medicines and follow-up measurements. The tissue images may also help explain why the heart is weak. Ejection fraction is one part of this assessment. [3,6]
A pattern suggesting inflammation	May lead to further assessment, monitoring and individual advice about activity during recovery. Symptoms, blood tests and other findings are considered together. [6,13]
A pattern of scar	Its location and extent may guide investigation of the cause, rhythm assessment or follow-up. Scar does not by itself mean that damage is happening now. [6]
An abnormal stress blood supply	The amount of muscle affected and your symptoms help determine whether medicines, further coronary assessment or a procedure should be considered. [5]
A valve leak or unusual blood flow	Measuring the flow and its effect on the chambers can help decide what monitoring or further specialist assessment is needed. [6]

If the findings are reassuring

A reassuring result may avoid further testing or provide a baseline for follow-up. A normal resting MRI does not substitute for stress perfusion. Agree what to do if symptoms continue.

If the answer is uncertain

Movement, an irregular heartbeat, some implants or an incomplete protocol can limit the study. The report should state any important limitation. Further imaging may be needed to answer the remaining question. [1,3]

At your consultation: ask which findings explain your symptoms or change your treatment, exercise or follow-up. Check who will discuss the report and whether further coronary assessment is needed.

Do not wait for a scan if symptoms become urgent

Call **999** for sudden chest pain or discomfort that does not go away, spreads to an arm, neck or jaw, or comes with sweating, nausea, light-headedness or breathlessness. **Do not drive yourself.** This applies even after a reassuring scan. [11]

Sources and further reading • Numbered links are clickable in the PDF.

1. ACR/RSNA. Cardiac MRI (2026).
2. ACR/RSNA. Coronary CT angiography (2026).
3. SCMR. Standardised CMR protocols (2020).
4. NICE CG95. Assessment of chest pain.
5. ESC. Chronic coronary syndromes guideline (2024).
6. SCMR. Clinical indications for CMR (2020).
7. NHS. Having an MRI scan.
8. Southampton. Stress cardiac MRI with adenosine.
9. BOOST coronary plaque MRI research (2026).
10. SCMR. Quantitative perfusion CMR consensus (2025).
11. NHS. Chest pain and urgent help.
12. Giollo et al. Published CMR image examples (2021).
13. SCMR/EACVI. T1, T2 and ECV mapping consensus (2017).

Version 1.1 • 22 November 2026 • Prepared for Dr Heseltine's clinical review. Local scan instructions take priority.