Dr Thomas Heseltine | Consultant Cardiologist

CARDIAC TESTS & PREVENTION

CT coronary angiography
What will my heart scan tell me?

The short answer

CT coronary angiography (CTCA) is a detailed CT scan of the arteries that supply your heart. Contrast dye injected into a vein lets us look for **plaque and narrowing**. It can help investigate chest pain and guide prevention, but it cannot predict a future heart attack with certainty. [1,2]

Two questions, one scan

Could my symptoms be angina?

CTCA looks for narrowing in the main coronary arteries that could restrict blood supply to the heart muscle. The result is interpreted alongside your symptoms and other tests.

What does this mean for my future risk?

CTCA can show plaque before it causes a major narrowing. Finding disease may change how actively we treat cholesterol and other cardiovascular risks.

What are we looking for?

The coronary arteries deliver oxygen-rich blood to your heart muscle. Plaque can develop silently within their walls over many years. A narrowing may cause angina; a heart attack often happens when a plaque is disrupted and a clot forms.

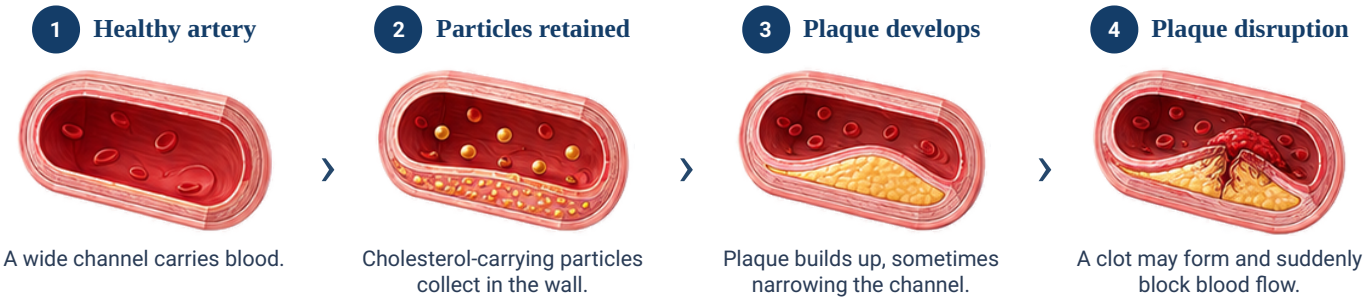

How atherosclerosis can develop. Illustrations explain the process; not every plaque progresses through these stages.

How is CTCA different from other tests?

A calcium score is not a CTCA

A calcium scan uses no contrast and measures **calcified** plaque. CTCA also shows non-calcified plaque and the blood channel. A calcium score of zero does not exclude all plaque.

It is not an invasive angiogram

CTCA uses a small cannula in an arm vein. A catheter is **not passed through an artery to your heart**, and a stent cannot be fitted during this scan. [2]

The right test for the right question

CTCA is often used when stable chest pain may be angina. It is not needed for every episode of chest pain, or as routine screening for everyone who feels well. [1,6]

CARDIAC TESTS & PREVENTION

Getting ready for your scan

Your appointment letter takes priority

Preparation varies between hospitals. Follow your scan team's instructions about food, caffeine, medicines and arrival time. Contact them before the appointment if anything is unclear. [3,4]

Caffeine

You may be asked to avoid tea, coffee, cola, energy drinks and other caffeine beforehand. Check the exact interval in your letter; do not assume all departments use the same rule.

Food and fluids

Follow the instructions about eating. Fasting policies vary. Stay normally hydrated unless you have been told to restrict fluids. Check in advance if fasting could affect your diabetes treatment.

Your usual medicines

Continue regular medicines unless your team advises otherwise. If a beta blocker has been prescribed for the scan, take it exactly as directed. Do not take extra doses yourself.

Kidney function and diabetes

Complete a kidney-function blood test if requested. Tell the team about kidney disease, recent serious illness and diabetes, including whether you take metformin or insulin. Ask for individual medication advice.

Conditions the team must know about

Tell the team about any previous reaction to CT contrast, severe allergies, asthma or wheeze, a very slow pulse or low blood pressure, and any possibility of pregnancy.

Comfort and practical needs

Wear comfortable clothes and be ready to remove metal from the chest area. Tell the team if you cannot lie flat, raise your arms or briefly hold your breath, or need communication or mobility support.

An important medicine check before the scan

Tell the team if you take **sildenafil, tadalafil, vardenafil or similar medicines**. These can interact dangerously with glyceryl trinitrate (GTN), the spray often used for CTCA. Ask exactly when to stop and restart them. **Do not stop treatment for pulmonary hypertension without specialist advice.** [3,4]

Bring with you

Your appointment letter, completed questionnaires and an up-to-date medication list, plus any inhaler or scan medicines you have been asked to bring. Check transport and driving advice in advance.

CARDIAC TESTS & PREVENTION

From arrival to going home

You are usually awake throughout. The pictures take only a short time; preparation and observation take longer. Allow the time stated in your appointment letter. [3,4]



Illustration of a typical set-up. Equipment and positioning vary.

1. **A short, open ring**
   The table moves through the scanner; this is not the long tunnel used for MRI.
2. **Pictures timed to your heartbeat**
   ECG stickers help the scanner capture images at the right moment.
3. **Brief breath-holds**
   You will practise holding still and following the breathing instructions.

1 Check in

The team confirms your history and medicines, checks your pulse and blood pressure, and places a cannula in an arm vein.

2 Prepare the heart

A beta blocker may slow the heartbeat. GTN spray may widen the coronary arteries. These are used only when suitable for you.

3 Take the images

You lie on your back with your arms raised. Contrast is injected during a brief breath-hold. Staff can see and hear you throughout.

4 Check and recover

The team checks the pictures and how you feel. You may wait briefly for observation before the cannula is removed.

What might I feel?

Contrast can cause a short warm flush, an unusual taste or a feeling that you are passing urine. GTN may cause a brief headache or light-headedness. Tell staff immediately about pain or swelling at the cannula, itching, wheeze or feeling unwell. [2,4]

What are the risks?

Radiation

CT uses X-rays. There is a small potential long-term cancer risk. Dose varies with the scanner and person, and is kept as low as practicable.

Contrast dye

An allergic reaction is possible; serious reactions are rare. Kidney risk is mainly relevant in people with impaired kidney function. Dye can occasionally leak around the cannula.

Scan medicines

A beta blocker can lower pulse or blood pressure; GTN can cause headache or dizziness. Your history and observations guide whether these are safe for you. [2,3,4]

Going home and getting the result

Follow your discharge advice. Most people can eat and resume usual activities. Drink normally unless fluid-restricted; **do not drive while dizzy or light-headed**. Ask who will give you the report and when, and contact the referring team if it does not arrive as agreed. A new rash needs medical advice; breathing difficulty or facial swelling needs urgent help via **999**.

CARDIAC TESTS & PREVENTION

Understanding your result

The report describes where plaque is, how extensive it is and whether it narrows an artery. A visible narrowing and a shortage of blood reaching the heart muscle are related, but are not the same thing. [1,5]

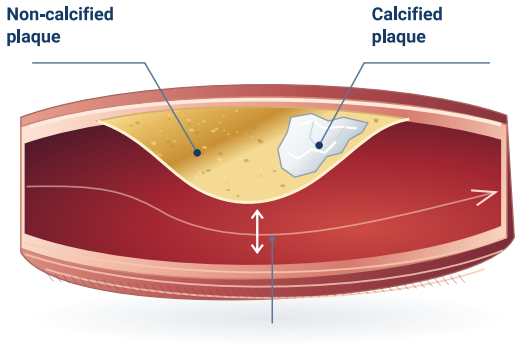

Anatomical illustration, not an actual CT image or a measured percentage narrowing.

Plaque

Disease in the artery wall. It can be present even when the blood channel remains quite open.

Stenosis

The medical word for narrowing. The percentage describes how much the artery's diameter is reduced.

Ischaemia

Too little blood supply to the heart muscle. A stress scan or another assessment may be needed to establish this.

What the report may show	What this usually means for the next step
No plaque or narrowing A normal, good-quality study	Reassuring for disease in the main coronary arteries. An invasive angiogram is usually unnecessary. Persistent symptoms still need an explanation.
Non-obstructive plaque Usually less than 50% narrowing	Plaque is present, but there is no major narrowing. Prevention matters. The finding may not explain the pain, so other causes can still need assessment.
Moderate narrowing 50–69%	The effect on blood supply may be uncertain. A stress MRI, stress echo, nuclear scan or selected CT-derived flow analysis may help guide the decision.
Severe narrowing or blockage 70% or more, or an occluded artery	Cardiology review is needed. Depending on the artery, symptoms and other findings, the next step may be medical treatment, further testing or an invasive angiogram.
An unclear part of the scan Non-diagnostic images	Motion, heavy calcium or other technical limitations can obscure the artery. This is not the same as a normal result; further assessment may be needed.

Percentages are estimates of diameter narrowing, not a percentage risk of heart attack. **A left main narrowing of 50% or more can be important**; location and the whole report matter. [1,5]

Other findings: CT may also show an unrelated change in the lungs or nearby structures. The report will explain whether separate follow-up is needed. [4]

A normal CTCA does not explain every form of chest pain

Small-vessel angina and coronary artery spasm can occur without a major narrowing on CTCA. Chest-wall, stomach, lung and other causes may also need consideration. **Continuing or changing symptoms deserve review, even after a reassuring scan.** [1,6]

CARDIAC TESTS & PREVENTION

Your results. Your prevention plan.

CTCA adds information about disease already present to what we know from your history and risk factors. The aim is not simply to label the scan: it is to agree a plan that helps you now and protects your future. [6,7]

Your clinical profile

Age, family history, blood pressure, cholesterol, smoking and other health conditions.

+

The plaque seen on CT

The amount and distribution of plaque, narrowing and selected plaque features.

+

Your symptoms and goals

Whether symptoms suggest angina, their effect on daily life and your treatment priorities.

Plaque matters even without a tight narrowing

More extensive coronary disease generally means greater future risk. A normal, good-quality CTCA is reassuring, not a lifetime guarantee. CT cannot predict exactly which plaque will cause a heart attack, or when. **Prevention still matters.** [5,6]

Turn the result into a personal plan

1. **Protect the arteries**
   If plaque is present, review LDL cholesterol and discuss appropriate cholesterol-lowering treatment. Agree a target and check the response.
2. **Treat the symptoms**
   Angina medicines may help. A stent or bypass is not automatic: treatment depends on symptoms, blood supply and high-risk anatomy.
3. **Address the whole risk profile**
   Control blood pressure and diabetes, avoid smoking, and agree a heart-healthy diet and activity plan suited to your symptoms.
4. **Agree what happens next**
   Confirm any further tests and follow-up. Aspirin is not automatic for every plaque finding; benefit and bleeding risk need individual assessment.

Treatment decisions draw on the full clinical picture, not the scan in isolation. [6,7,8]

Questions worth asking at your consultation

How much plaque is present, and does it explain my symptoms? Do I need another test?
What are my targets, who will review me, and what should I do if symptoms change?

Do not wait for a scan if chest pain becomes urgent

Call 999 for sudden chest pain or discomfort that does not go away, spreads to an arm, neck or jaw, or comes with sweating, nausea, light-headedness or breathlessness. Do not drive yourself. This applies even after a previously normal scan. [9]

In summary: Use the scan to guide symptom assessment, further tests and prevention—not simply to label the arteries.

Sources and further reading • Links are clickable in the PDF.

1. NICE CG95: assessment and diagnosis of chest pain
2. ACR/RSNA RadiologyInfo: coronary CT angiography
3. Cambridge University Hospitals: cardiac CT angiogram
4. Royal Free London: having a cardiac CT scan
5. SCCT/ACC/ACR/NASCI: CAD-RADS 2.0 (2022)
6. ESC: chronic coronary syndromes guideline (2024)
7. NICE NG238: cardiovascular risk and lipid modification
8. NICE CG126: management of stable angina
9. NHS: chest pain and when to call 999

Version 1.0 • Prepared September 2026 for Dr Heseltine's clinical approval. Local scan instructions take priority.